

**A NOTE ON A TWO-HEADED EMBRYO OF THE JAVANESE COWNOSE RAY
RHINOPTERA JAVANICA MULLER AND HENLE**

ABSTRACT

An abnormal embryo of the Javanese cownose ray *Rhinoptera javanica* Muller and Henle, collected from Calicut Fish Market is reported by describing the structural peculiarities and their probable causes.

STRUCTURAL peculiarities among sharks and rays have often been reported from different regions (Gill, 1896 ; Gudger, 1933 ; Bigelow and Schroder, 1953 ; Menon, 1957 ; Luther, 1961 ; Bennet, 1964 ; Bensam, 1965). During a visit to the Calicut Central Fish Market on 4.9.'84 the author came across an abnormal embryo of the Javanese cownose ray, *Rhinoptera javanica* Muller and Henle (Pl. I). The specimen is described here along with some additional details about the mother gathered from enquiries.

The author wishes to express his sincere thanks to shri C. Mukundan for critically going through the manuscript and suggesting improvements.

Material and Methods

Since the mother ray was cut to pieces for sale its exact measurements could not be taken. However, the available cut-pieces were rearranged (Pl. II A) and the material was identified as *R. javanica*. It was reported by the fish vendor that the mother fish, weighing 40 kg, was caught off Nellore on the Andhra Coast by hooks and line, iced well and transported to Calicut by train for sale. While cutting the fish the abnormal embryo present in the uterus of the mother attracted the attention of the vendor and it was removed without damage. Only one embryo was found in the uterus and it was abnormal in size, with two heads and two anal spines. The measurements and

counts made on the abnormal embryo are given in Table 1, along with the measurements of the normal embryos of the species given by James (1962). The specimen is deposited at the museum of the Calicut Research Centre of Central Marine Fisheries Research Institute.

Description of the embryo

Body asymmetrical, depressed and smooth. The two heads are distinct from the disc and are fused together laterally (Pl. II B). The snouts of both the heads blunt with a median notch. On the dorsal side of each head four ridges are seen. Pectorals, two in number, are not fused with the sides of the heads giving the part a 'neck-like' appearance. At the anterior side of each pectoral a small 'horn-like' projection is seen (Pl. III A). The right pectoral is bigger than the left with almost normal shape, whereas the left one is smaller, almost rudimentary in nature. The embryo has one dorsal and two ventral fins which are normal in shape. There is a mid ridge found between the two heads on the lower part. Just below this, in between the 'neck-like' notches there is a small ridge. Each head is provided with a pair of eyes, spiracles and a mouth which are normal in shape. Spiracles almost equal to eyes and are situated behind the eyes. A single umbilical scar found on the anterior part of the ventral region, but the umbilical connection is lost. Five gill openings

TABLE 1. *A comparison of the present abnormal embryo with that of the normal embryos described by James (1962)*

Characters	Abnormal	Normal	
		1	2
Place of collection	Calicut	Pudumadam	Kilakarai
Date of collection	4.9.'84	23.12.'59	17.1.'62
Sex	Female	Female	Female
Weight of the embryo (g)	700	240	350
Width of disc (distance between the tips of pectorals)	32.00	25.40	31.00
Length of disc (Snout to tip of ventrals)	21.9 (R) 19.4 (L)	16.50	19.40
Orbit (horizontal diameter)	1.00	0.80	0.90
Length of tail	39.00	51.30	58.10
Height of dorsal	2.50	1.10	1.05
Length of ventral	3.90	3.00	3.45
Width of mouth	5.00 (R) 4.90 (L)	2.80	3.55
Point of fusion of heads to the tip or ventral	18.40	—	—
Length of disc (tip of pectorals to the beginning of the knotches)	15.6 (R) 11.4 (L)	—	—
Distance between the snout knotches	11.90	—	—

* All measurements given in centimetres.

(Pl. III B) are seen on the outer sides of the two heads and are situated just above the origin of the pectorals. The gill openings on the inner sides (Pl. III A) are found fused together except the first gill opening found on the left side of the right head. In the fused side there are only three pairs traceable (In the normal embryos five pairs of gills are found on the ventral side in between the mouth and the umbilical scar). Teeth found on both the jaws. Tail long, slender and whip-like with two non-serrated curved spines at its beginning, just below the dorsal fin, placed one above the other. (The mother had only one serrated spine near the origin of the tail).

Remarks

So many causes have been attributed to the abnormalities in elasmobranch embryos by earlier workers (Melouk, 1949 ; De Beer,

1958 ; Smith, 1961 ; Luther, 1961). The non-development of the 'epidermal bud' which is said to represent a point of growth regulating the fusion of the pectoral to the branchial crest (Melouk, 1949) may be held responsible for the abnormality in the disc. The presence of two heads, four eyes, four spiracles, two mouths, four rows of gills and two caudal spines in the present material shows that this is a case of fusion of two embryos at the time of development inside the mother's uterus.

James (1962) had noticed a majority of the females of this species carrying one embryo. But it may be pointed out here that the number of embryos each female would give birth to, in a season could not be stated with certainty since it is commonly known that these fishes eject out the advanced embryos on capture and hauling up into boats, which under normal conditions might involve some

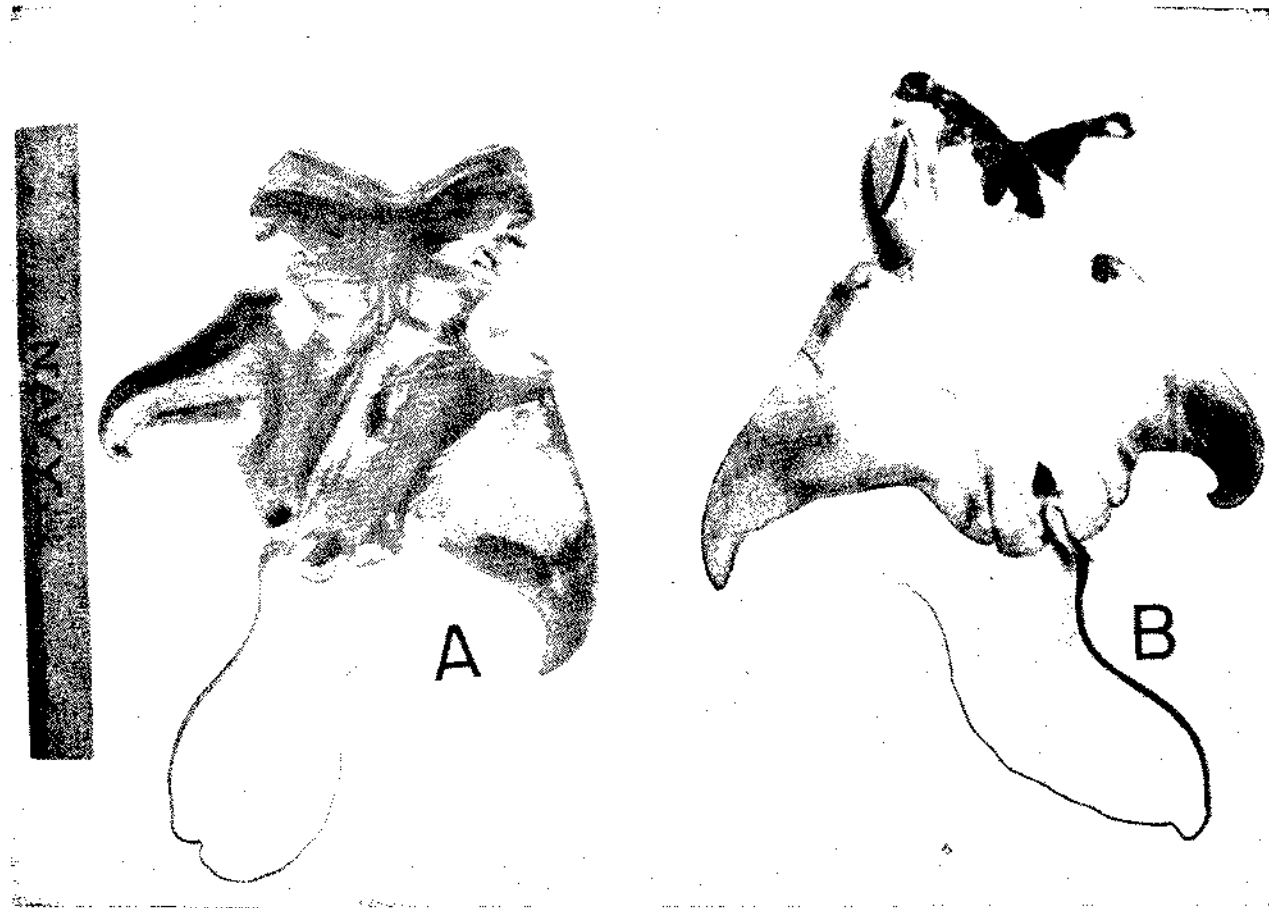

PLATE I. A. Dorsal view of the embryo and B. Ventral view of the embryo showing the umbilical scar.

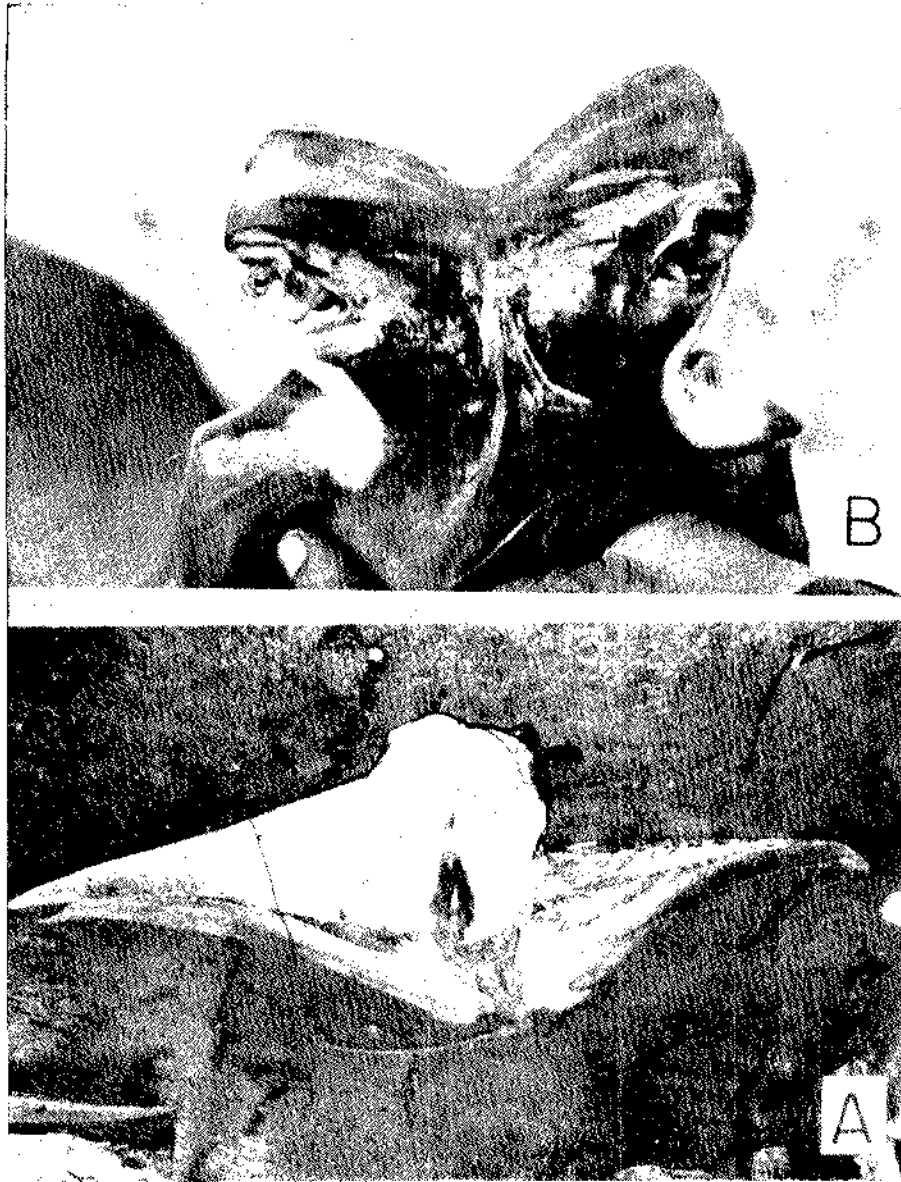


PLATE II - A. The cut pieces of the mother - rearranged and B. The fused heads of the embryo - dorsalview

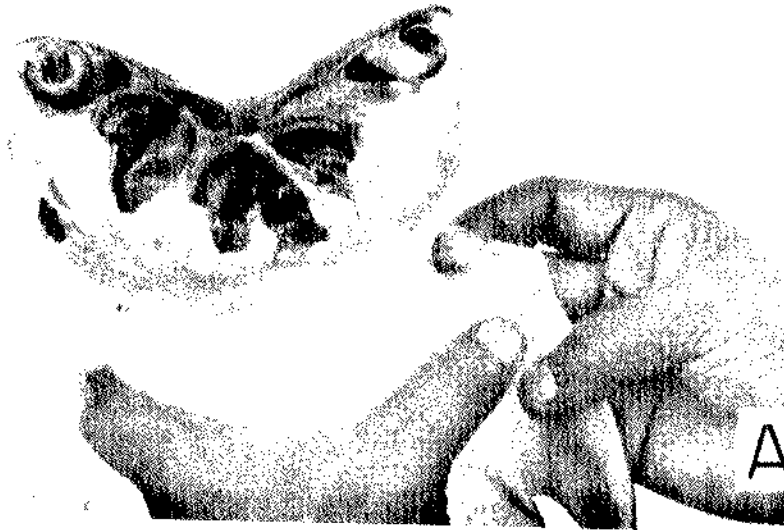
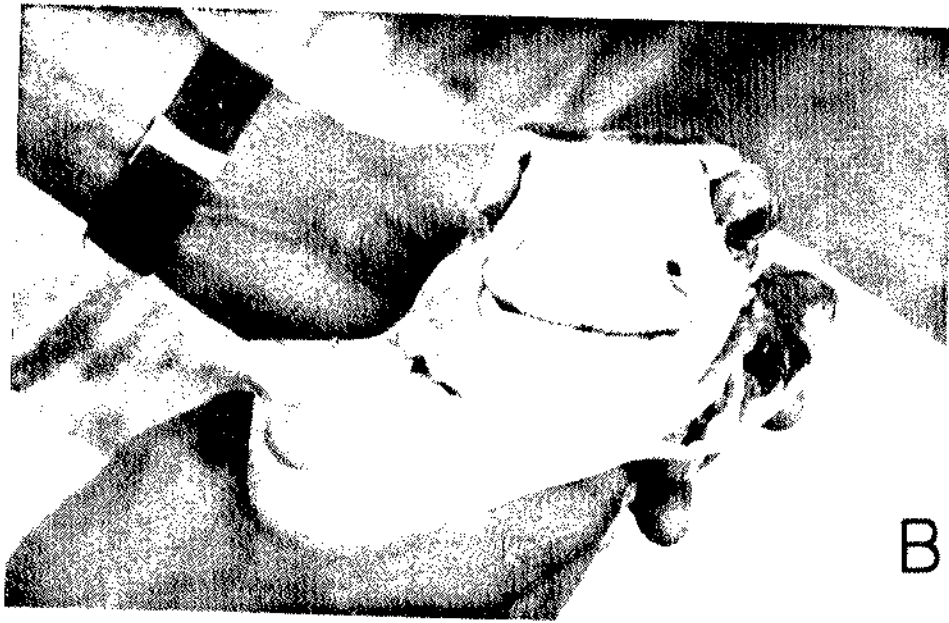


PLATE III. A. Lateral view of the fused heads showing the fused gills and the 'horn-like' projection of the left pectoral and B. Ventral view of one of the heads showing the gills in the mouth and the 'horn-like' pectoral projection.

more time. The present embryo, being abnormal and bigger in size would have found it difficult to get out through the cloaca and thereby stayed for a longer duration inside the mother's body. While comparing the length of the body parts with the

weight of the embryo there is much difference seen between the present abnormal material and normal material described by James (1962). In the present material invariably the body parts have less length when compared to its weight.

Central Marine Fisheries
Research Institute,
Cochin-682 031

S. LAZARUS**

REFERENCES

- BENNET, P. S. 1964. *J. mar. biol. Ass. India*, 6 (2) : 316-317.
- BENSAM, P. 1965. *Ibid.*, 7 (1) : 206-208.
- BIGELOW, H. B. AND W. C. SCHRODER 1953. *Mem. Sear Found. Mar. Res.*, 1, pt. II.
- * DE BEER, G. R. 1958. *Embryos and Ancestors*, Oxford.
- * GILL, T. N. 1896. *Proc. U. S. Nat. Mus.*, 18 : 195-198.
- GUDGER, E. W. 1933. *Amer. Mus. Novit.*, No. 600.
- JAMES, P. S. B. R. 1962. *J. mar. biol. Ass. India*, 4 (2) : 217-223.
- LUTHER, G. 1961. *Ibid.*, 3 (1 & 2) : 198-203.
- * MELOUK, M. A. 1949. *Publ. Marine Biol. Sta. Ghardaga*, 7.
- MENON, M. D. 1957. *J. Zool. Soc. India.*, 9 (2) : 200-207.
- SMITH, J. L. B. 1961. *The sea fishes of Southern Africa*, P. 504.

* Not consulted in original.

* Present address: Vizhinjam Research Centre of CMFRI, Vizhinjam, Trivandrum.